

---

# Rapid Resolution of Coronary Artery Spasm Complicated by Acute Systolic Heart Failure with Antirejection Therapy in Acute Orthotopic Heart Transplant Rejection

Howard Lan\*, Liset Stoletniy, Antoine Sakr and Anthony Hilliard

Loma Linda University Medical Center, Loma Linda, CA, USA

\*Corresponding author: Howard Lan, Loma Linda University Medical Center, Anderson Street, Loma Linda, USA.

**Received:** April 18, 2022; **Accepted:** April 29, 2022; **Published:** May 21, 2022

## Abstract

We report a case of rapid resolution of Coronary Artery Spasm (CAS) and improvement of systolic heart failure by antirejection therapy with methylprednisolone in the setting of acute Orthotopic Heart Transplant (OHT) rejection. The proposed mechanism of action is reduced microvascular inflammation from steroid therapy resulting in enhanced vasomotor response, resolution of coronary artery spasm, and improved hemodynamic. The case report has treatment implications for patients in acute OHT rejection with coronary artery spasm. Antirejection therapy with steroid may be helpful in treating life threatening cardiac conditions in patients with acute OHT rejection and coronary artery spasm.

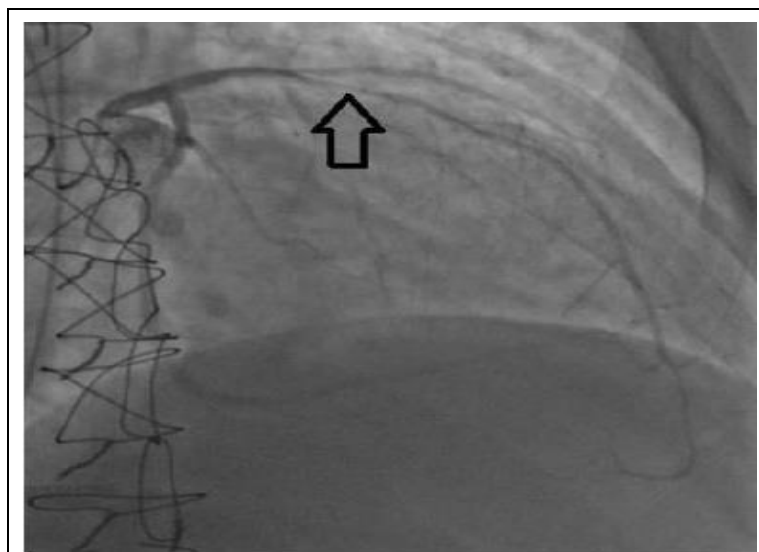
**Keywords:** Antibody mediated rejection; Coronary artery spasm; Orthotopic heart transplant; Systolic heart failure

## Introduction

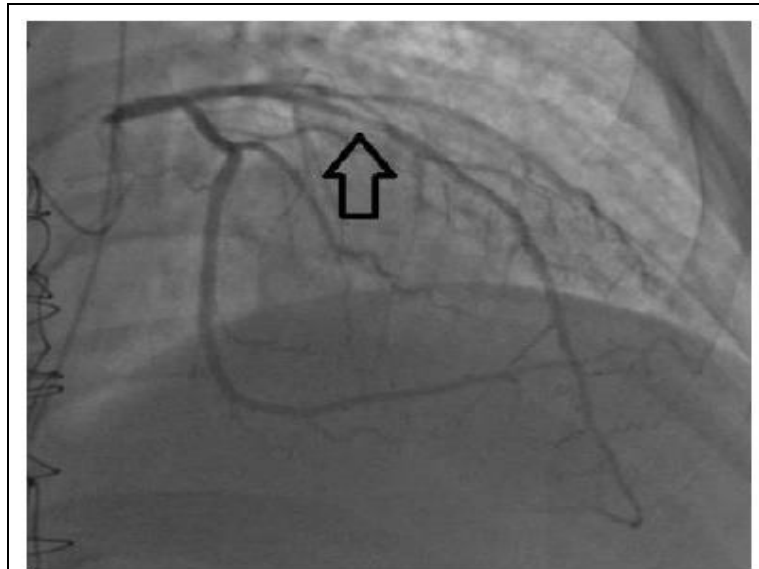
Coronary Artery Spasm (CAS) is defined as vasoconstriction of epicardial coronary artery causing vessel narrowing or occlusion [1]. CAS has been described as an early stage of cardiac allograft vasculopathy [2]. CAS involves an imbalance of autonomic nervous system, endothelial dysfunction, and abnormal smooth muscle reactivity [1]. In acute Orthotopic Heart Transplant (OHT) rejection, in addition to attenuated nitric oxide production [3], microvascular inflammation [4] may also be a contributor to CAS. In this case report, we describe the pathophysiology and clinical presentation of a unique case of CAS, in acute OHT rejection, which partially improved with sublingual nitroglycerin but completely resolved after antirejection therapy with steroid within 24 h.

## Case Report

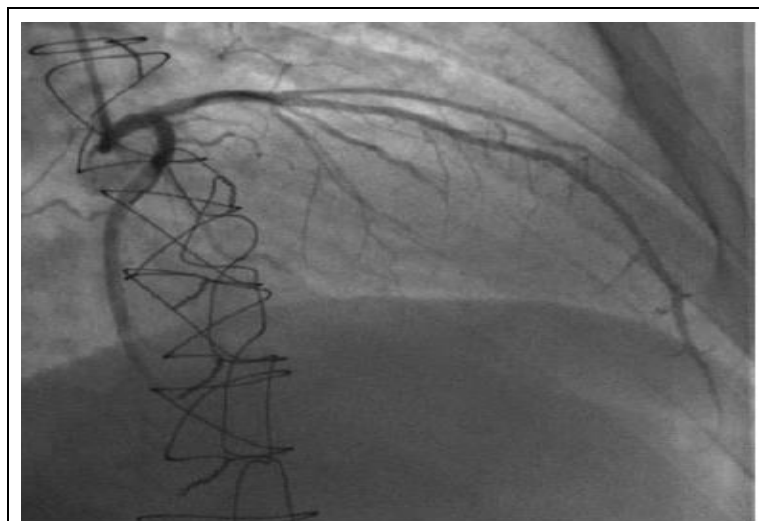
29 year-old male with history of dilated cardiomyopathy and OHT two years prior, who complained of dyspnea on exertion, orthopnea, and paroxysmal nocturnal dyspnea for one week. Patient underwent outpatient left and right cardiac catheterization and showed diffuse mid Left Anterior Descending (LAD) narrowing estimated at 75% throughout (Figure 1) with diagonal involvement, which were not present one year prior. After administration of sublingual nitroglycerin, the stenoses marginally improved (Figure 2) but Thrombolysis in Myocardial Infarction (TIMI) 2 slow flow throughout the coronary bed remained. The Left Ventricular End Diastolic Pressure (LVEDP) was elevated at 26 mmHg. Given the patient's history and invasive study findings, he was directly admitted to the cardiac care unit for suspected acute OHT rejection. While waiting for test results to confirm rejection, patient was started on antirejection immunosuppressive therapy including intravenous methylprednisolone [5-7]. On the following day, patient underwent repeat left cardiac catheterization which showed resolution of the LAD and diagonal stenoses (Figures 3 and 4), normalization of coronary flow (TIMI 3), and significantly improved LVEDP of 14 mmHg. Laboratory studies collected on admission revealed the presence of new human leukocyte antigen HLA-DQ, HLA-DQ7, and anti-complement C1q antibodies indicating that the patient had acute antibody mediated rejection (AMR). Echocardiogram showed a reduction in left ventricular ejection fraction from 75%, one month prior, to 45% with elevated filling pressures. Individualized treatment plan for AMR was escalated to include plasmapheresis [5,8], intravenous immunoglobulin [5,8], and antithymocyte globulin [9,10] infusion. Patient's clinical status improved with OHT antirejection therapy and was discharged home on hospital day ten.



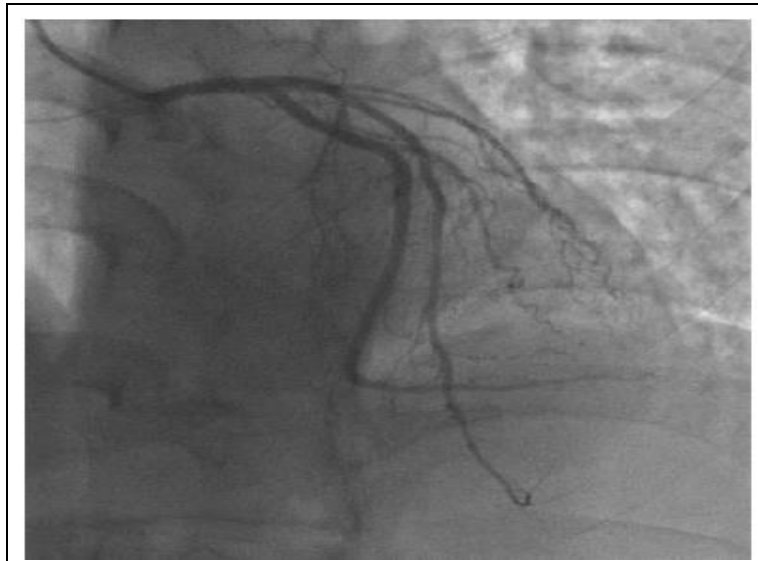
**Figure 1:** Demonstration of coronary artery spasm in acute orthotopic heart transplant rejection with diffuse mid left anterior descending narrowing with diagonal involvement. Arrow shows the most significant lesion with 75% stenosis at the mid left anterior descending artery.



**Figure 2:** After administration of sublingual nitroglycerin, the stenosis marginally improved but slow flow throughout the coronary bed remained. Arrow shows slight improvement in mid left anterior descending stenosis.



**Figure 3:** Right anterior oblique with cranial angulation view demonstration complete resolution of left anterior descending coronary artery spasm after one day of antirejection therapy with methylprednisolone.



**Figure 4:** Left anterior oblique with cranial angulation view demonstration complete resolution of left anterior descending coronary artery spasm after one day of antirejection therapy with methylprednisolone.

## Discussion

Coronary Artery Spasm (CAS) in OHT has been reported as early as 1981 [11], Buda induced CAS in an OHT patient with intravenous ergonovine maleate. Subsequent reports demonstrated the resolution of CAS in OHT patients by intracoronary nitroglycerin [12,13] and sublingual nitroglycerin [14]. However, we present the first case of CAS in the setting of acute OHT rejection with complete resolution of CAS after initiation of antirejection therapy with methylprednisolone. Secondly, the physiologic response to antirejection therapy was immediate, within 24 h, as evidenced by resolution of CAS and normalization of LVEDP.

The pathophysiology of CAS is complex and involves an imbalance of autonomic nervous system, endothelial dysfunction, and abnormal smooth muscle reactivity [1]. However, patients with OHT are denervated suggesting that autonomic nervous system and cardiac innervation are not essential mechanisms in all CAS [11-14]. At the molecular level, mediators including acetylcholine, serotonin, and histamine trigger the release of nitric oxide by endothelin resulting in vasodilation [1]. On the other hand, the same mediators stimulate vascular smooth muscle cells resulting in vasoconstriction. With endothelial dysfunction, the balancing mechanism is impaired and results in vasoconstriction and spasm [1].

Molecular pathways involved in CAS in acute OHT rejection are even more complex than CAS in non-transplanted patients. Factors contributing CAS in acute OHT rejection include complement deposition, impaired endothelial adhesion to extracellular matrix, lower nitric oxide production, and reduction of endothelium dependent relaxation to acetylcholine [3]. Furthermore, endothelial Notch ligand Dll4 is upregulated in AMR which induces macrophage polarization into a pro-inflammatory state and intravascular macrophage infiltrate. The overall result is microvascular inflammation [4].

Previously, Schlaifer and Mills compared the vasomotor response in epicardial coronary artery before and after immunosuppression with steroid in acute OHT rejection [15]. Impaired coronary blood flow response to acetylcholine was found at baseline in all nine subjects. More importantly, after three days of intense intravenous methylprednisolone therapy, repeat invasive study showed a trend towards greater dilation of epicardial coronary artery with administration of nitroglycerin. The study demonstrated that steroid therapy in acute OHT rejection reduced microvascular inflammation and improved epicardial coronary artery vasomotor response, which explains our observations in the presented case.

The current case report may also have important treatment implications in patients with CAS who are in acute OHT rejection. CAS can cause life threatening conditions including coronary artery occlusion, coronary ischemia, ventricular fibrillation, cardiac arrest [11,14,16], and in our case acute decompensated systolic heart failure [17,18]. The CAS marginally improved with sublingual nitroglycerin but did not achieve complete distal flow normalization until patient received antirejection immunosuppressive therapy for acute OHT rejection with methylprednisolone. This suggests that patients in acute OHT rejection and severe CAS, treatment with vasodilators may not be adequate and may require the initiation of antirejection therapy for complete resolution.

## Conclusion

We report the first case of CAS in acute OHT rejection with complete resolution of CAS and improved systolic heart failure by antirejection therapy with methylprednisolone. Furthermore, treatment response was immediate, within 24 h. The proposed mechanism of action is reduced microvascular inflammation from steroid therapy resulting in enhanced vasomotor response, resolution of CAS, and improved hemodynamics. This case report suggests important treatment implications in patients with CAS and acute OHT rejection, especially if patient is in life threatening clinical situations including coronary artery occlusion, coronary ischemia, severe heart failure, or fatal arrhythmias. Early initiation of steroid therapy may help to improve CAS and could potentially serve as a lifesaving intervention.

## REFERENCES

1. Lanza GA, Careri G, Crea F. Mechanisms of Coronary Artery Spasm. *Circulation.* 2011; 124: 1774-1782.
2. Bisognano JD, Lindenfeld J, Hammond E, et al. Coronary Artery Vasospasm Causing Acute Myocardial Infarction in a Heart Transplant Recipient. *J Heart Lung Transplant.* 2005; 24: 355-358.
3. Cable DG, Hisamochi K, Schaff HV. A Model of Xenograft Hyperacute Rejection Attenuates Endothelial Nitric Oxide Production: A Mechanism for Graft Vasospasm. *J Heart Lung Transplant.* 1999; 18: 177-184.
4. Pabois A, Pagie S, Gérard N, et al. Notch Signaling Mediates Crosstalk Between Endothelial Cells and Macrophages Via Dll4 And IL6 in Cardiac Microvascular Inflammation. *Biochem Pharmacol.* 2016; 104: 95-107.
5. Costanzo MR, Dipchand A, Starling R, et al. The International Society of Heart and Lung Transplantation Guidelines for the Care of Heart Transplant Recipients. *J Heart Lung Transplant.* 2010; 29: 914-956.
6. Auphan N, DiDonato JA, Rosette C, et al. Immunosuppression by Glucocorticoids: Inhibition of NF-Kappa B Activity through Induction of I Kappa B Synthesis. *Science.* 1995; 270: 286-290.

7. Snyder DS, Unanue ER. Corticosteroids Inhibit Murine Macrophage Ia Expression and Interleukin 1 Production. *J Immunol.* 1982; 129: 1803-1805.
8. Thrush PT, Pahl E, Naftel DC, et al. A Multiinstitutional Evaluation of Antibody-Mediated Rejection Utilizing the Pediatric Heart Transplant Study Database: Incidence, Therapies and Outcomes. *J Heart Lung Transplant.* 2016; 2498: 30192-30199.
9. Frist WH, Merrill WH, Eastburn TE, et al. Unique Antithymocyte Serum Versus OKT3 for Induction Immunotherapy after Heart Transplantation. *J Heart Transplant.* 1990; 9: 489-494.
10. Uber WE, Uber LA, VanBakel AB, et al. CD3 Monitoring and Thymoglobulin Therapy in Cardiac Transplantation: Clinical Outcomes and Pharmacoeconomic Implications. *Transplant Proc.* 2004; 36: 3245-3249.
11. Buda AJ, Fowles RE, Schroeder JS, et al. Coronary Artery Spasm in the Denervated Transplanted Human Heart: A Clue to Underlying Mechanisms. *Am J Med.* 1981; 70: 1144-1149.
12. Cattan S, Drobinski G, Artigou JY, et al. Coronary Artery Spasm in a Transplant Patient. *Eur Heart J.* 1988; 9: 557-560.
13. Dalal JN, Brinker JA, Resar JR. Coronary Artery Spasm in the Transplanted Human Heart. A Case Report. *Angiology.* 1996; 47: 291-294.
14. Goldenberg IF, Levine TB. Coronary Artery Spasm in a Denervated Orthotopic Transplanted Human Heart. *Cathet Cardiovasc Diagn.* 1986; 12: 44 -47.
15. Schlaifer JD, Mills RM. Effect of Low Molecular Weight Heparin on Coronary Endothelial Function in Acute Cellular Heart Transplant Rejection. *Am J Cardiol.* 2000; 86: 117-120.
16. Romagnoli E, Lanza GA. Acute Myocardial Infarction with Normal Coronary Arteries: Role of Coronary Artery Spasm and Arrhythmic Complications. *Int J Cardiol.* 2007; 117: 3-5.
17. Mancio J, Caeiro D, Faria R, et al. A 75-Year-Old Woman with Chest Pain and Transient Severe Left Ventricular Systolic Dysfunction. *Rev Port Cardiol.* 2015; 34: 621.
18. Oda S, Fujii Y, Takemoto H, et al. Heart Failure in Which Coronary Spasms Played an Important Role. *Intern Med.* 2014; 53: 227-232.